PART 4 | Trauma

CHAPTER

29 Torso and pelvic trauma

Learning objectives

To understand:

- The importance of physiology over anatomy in the management of trauma
- The gross surgical anatomy of the chest and abdomen
- The pathophysiology of torso injury
- The clinical assessment in the injured patient
- The use of special investigations and their limitations
- The operative approaches to the thoracic cavity
- The special features of an emergency department thoracotomy for haemorrhage control
- The indications for, and techniques of, the trauma laparotomy
- The philosophy of damage control resuscitation
- The management of trauma to the pelvis

INTRODUCTION

Injury seldom respects anatomical boundaries, hence the division of the body into the abdomen and the thorax is artificial. Therefore, injury to the torso with its associated physiological consequences is more appropriate. The torso is generally regarded as the focal point of the human body, consisting of the chest, abdomen and pelvis and not including the head, neck, arms and legs. About 42% of all deaths are the result of brain injury, but some 39% of all trauma deaths are caused by major haemorrhage, usually from torso injury (*Figure 29.1*).

Historically, injury was treated on an anatomical basis; however, it has become clear that physiology should be the over-riding consideration. The driver of successful resuscitation is therefore the preservation of normal physiology. Techniques such as damage control resuscitation and its key component damage control surgery have dramatically improved survival through an understanding of the best techniques required to restore physiological stability (see *Chapters 1, 26 and 27*).

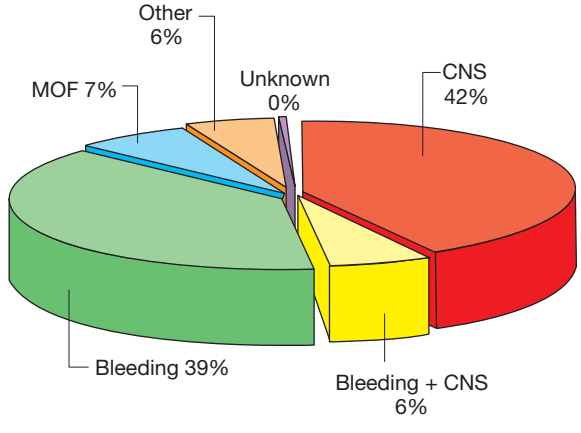

Figure 29.1 Causes of death in trauma. CNS, central nervous system; MOF, multiple organ failure.

INJURY MECHANISMS ASSOCIATED WITH TORSO TRAUMA

Injury consistently traverses different anatomical zones of the body, affecting structures on both sides of traditional anatomical zones. These zones are known as junctional zones.

Junctional zones

The key junctional zones are:

- between the neck and the thorax;
- between the thorax and the upper limbs;
- between the thorax and the abdomen;
- between the abdominopelvic structures and the groin.

These zones represent surgical challenges in terms of both diagnosis of the area of injury and the required surgical approach. Such factors have to be balanced against the physiological stability of the patient.

Root of the neck

Most injuries affecting the base of the neck may also affect the upper mediastinum and thoracic inlet. Choice of access is determined by the need for surgical control of the vascular structures contained within.

The mediastinum

The mediastinum, with its major vessels and the heart, is also an extremely high-risk area for penetrating wounds. Any wound in this region should immediately raise the suspicion of a major vascular or an associated cardiac injury, even in the absence of initial gross physical signs.

Diaphragm

The thorax and abdomen are separated by the diaphragm, which is mainly responsible for breathing, allowing movement

during breathing between the fourth and eighth intercostal space. Any penetrating injury below the nipples on the chest may therefore have penetrated the diaphragm and entered the abdomen. Injuries in this junctional zone, therefore, should be investigated as if both cavities had been penetrated (*Figure 29.2*). In blunt trauma, rupture of the diaphragm can result in migration of abdominal viscera into the chest, with left-sided hemidiaphragm rupture being more common.

Pelvic structures

The pelvis contains a large plexus of vessels, both venous and arterial. Should injury occur, control of haemorrhage can prove to be exceptionally difficult and may require control of both arterial inflow and venous outflow. Angioembolisation can be a very useful adjunct to treatment, especially with deep pelvic injuries.

Summary box 29.1

Junctional zones

- Between neck and the thorax
- Between thorax and upper limbs
- Between thorax and the abdomen
- Between the abdominopelvic structures and the groin

CRITICAL PHYSIOLOGY

Resuscitation of all injuries to the chest and abdomen should follow the latest Advanced Trauma Life Support (ATLS) principles (*Table 29.1*; see *Chapters 26 and 27*).

TABLE 29.1 Advanced Trauma Life Support principles of resuscitation.

C	Catastrophic haemorrhage
A	Airway
B	Breathing
C	Circulation
D	Disability (neurology)
E	Environment and exposure

TABLE 29.2 Clinical indicators of potential ongoing bleeding in torso trauma.

Physiological	Increasing respiratory rate
	Increasing pulse rate
	Falling blood pressure
	Rising serum lactate
Anatomical	Visible bleeding
	Injury in close proximity to major vessels
	Penetrating injury with a retained missile

Haemorrhage is the major problem. This may be obvious at the time of evaluation; however, in the young physically fit individual, bleeding may produce no or only minimal changes in vital measures and, therefore, be difficult to assess (*Table 29.2*). Although obvious injury may be present, traditional indicators (such as pulse rate), in isolation, are unreliable.

Bleeding occurs from five major sites – '**one on the floor and four more**':

- external – 'floor';
- chest;
- abdomen (including the retroperitoneum);
- pelvis;
- extremities.

THORACIC INJURY

Thoracic injury accounts for 25% of all severe injuries. In a further 25%, it may be a significant contributor to the subsequent death of the patient. In most of these patients, the cause of death is haemorrhage. In excess of 80% of patients with chest injury can be managed non-operatively. The key to a good outcome is early physiological resuscitation followed by a correct diagnosis.

Investigation

Routine investigation in the emergency department of injury to the chest is based on clinical examination, supplemented by appropriate imaging.

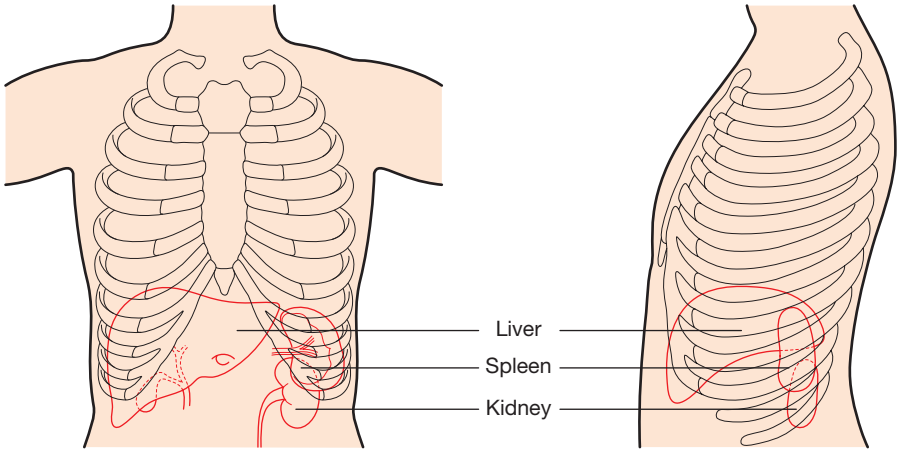

Figure 29.2 The anatomical extent of the abdomen.

Ultrasound – extended focused assessment with sonography for trauma (eFAST)

Ultrasound can be used to differentiate between contusion and the actual presence of blood. Extended focused assessment with sonography for trauma (eFAST) is becoming the most common investigation. The technique uses sonographic assessment in the chest, looking for a cardiac tamponade or free blood and air in the hemithoraces, and assessment for blood in the abdominal cavity, in the paracolic gutters, subdiaphragmatic spaces and pelvis.

Finger thoracostomy

In the physiologically grossly unstable patient, where physical examination is inconclusive and there is no time for radiological investigations, bilateral finger thoracostomy can be a diagnostic procedure as well as a therapeutic one, and the benefits of undertaking it often outweigh the risks. It is undertaken by making a 5-cm skin incision on the fifth rib just anterior to the mid-axillary line. The intercostal muscles are then separated just above the fifth rib and the pleural cavity entered. A finger is then inserted and a pleural sweep made to ensure the pleural cavity has been entered.

Chest radiograph

In those cases where the patient is physiologically non-compromised or the spine is at risk, an anteroposterior (AP) supine chest radiograph is usually the simplest initial investigation. It will provide good information regarding tracheal deviation, lung and mediastinal pathology as well as skeletal injury.

In penetrating injury, it may be more helpful for the radiograph to be performed with the patient positioned erect, as this will best reveal a small pneumothorax, fluid meniscus, air–fluid level or the presence of free gas under the diaphragm, indicating the presence of a hollow abdominal viscus perforation. Note that up to 300 mL of blood may pool behind the domes of the diaphragm, and may not be visible even in the erect view.

The presence of thoracic skeletal injury should alert the clinician to the possibility of adjacent thoracic or abdominal visceral injury. Rupture of the thoracic aorta can be related to fractures of the first and second rib, bilateral clavicular fracture and fracture of the sternum, thoracic spine or scapula. Fracture of the lower ribs can be related to injury of the liver or spleen. Fracture of the ribs, irrespective of site, can be related to injury to the lung parenchyma or thoracic wall vasculature, causing pneumothorax, haemothorax or lung contusion.

Computed tomography scan

The computed tomography (CT) scan with contrast allows for three-dimensional reconstruction of the chest and abdomen, as well as of the bony skeleton. It has become the principal and most reliable examination for major injury in trauma. In blunt chest trauma, the CT scan will allow the definition of fractures, as well as showing haematomas, pneumothoraces and pulmonary contusion. In penetrating trauma, the scan may show the track or presence of the missile and allow the proper planning of definitive surgery. However, although the presence of an isolated rupture of the diaphragm with migration of abdominal contents into the chest can be detected by CT scan, in injury without migration the diagnosis will not be obvious.

The pitfalls of investigation are:

- failure to assess tracheal shift immediately above the sternal notch clinically (deviation of the trachea occurs away from the affected side in tension pneumothorax and towards the affected side in lung collapse);
- failure to percuss and auscultate both front and back in a supine patient (an inflated lung will 'float' on a haemothorax, so auscultation from the front may sound normal);
- failure to pass a nasogastric tube if rupture of the diaphragm is suspected; a chest radiograph will show the nasogastric tube apparently within the chest cavity;
- a supine chest radiograph can show a haemothorax as a homogeneous increase in opacity of the hemithorax – this can cause confusion between the darker side and the lighter side as to which may be a haemothorax (less radiolucent) or a pneumothorax (more radiolucent); look carefully for lung markings and do not drain the wrong side;
- pursuing radiological investigation (radiography or CT scan) instead of resuscitation in the unstable patient.

Summary box 29.2

Investigation of chest injuries

- Directly or indirectly involved in >50% of trauma deaths
- More than 80% can be managed non-operatively
- A chest radiograph is the investigation of first choice
- Finger thoracostomy can be diagnostic and therapeutic
- A pan-CT scan provides rapid diagnosis

Management

In penetrating injury, most patients who have suffered injury to the chest can be managed with appropriate resuscitation and insertion of an intercostal drain.

If a sucking chest wound is present, this should not be fully closed but should be covered with a piece of plastic, closed on three sides to form a one-way valve, and thereafter an underwater chest drain should be inserted remote from the wound. No attempt should be made to close a sucking chest wound until controlled drainage has been achieved, in case a stable patient with an open pneumothorax is converted into an unstable patient with a tension pneumothorax.

In blunt injury, most bleeding occurs from the intercostal or internal mammary vessels and it is relatively rare for these to require surgery. If bleeding does not stop spontaneously, the vessels can be embolised, via an interventional radiological approach, or treated operatively, during which the vessels can be tied off or encircled. In blunt chest compressive injury, particularly in the presence of a flail chest, there can be an associated lung contusion.

The patient in extremis with exsanguinating chest haemorrhage is discussed in ***Emergency department thoracotomy or sternotomy***.

Life-threatening injuries can be remembered as the 'deadly dozen'. Six are immediately life-threatening and should be

Summary box 29.3

Closed management of chest injuries

- More than 80% of chest injuries can be managed with the insertion of an intercostal drain only
- Do not close a sucking chest wound until a drain is in place
- If bleeding persists, the chest will need to be opened and direct haemostatic control is obtained

sought and managed during the primary survey and six are potentially life-threatening and should be detected during the secondary survey (*Table 29.3*). A high index of suspicion must be maintained thereafter to diagnose the potential threats to life, as their symptoms and signs can be very subtle. Early consultation and referral to a trauma centre is advised in cases of doubt.

Immediate life-threatening injuries

Airway obstruction

Early intubation is very important, particularly in cases of neck haematoma or possible airway oedema. Airway distortion can be insidious and progressive and can make delayed intubation more difficult if not impossible.

Tension pneumothorax

A tension pneumothorax develops when a 'one-way valve' air leak occurs either from the lung or through the chest wall. Air is sucked into the thoracic cavity without any means of escape, completely collapsing and then compressing the affected lung. The mediastinum is displaced to the opposite side, decreasing venous return and compressing the opposite lung.

The most common causes are penetrating chest trauma, blunt chest trauma with a parenchymal lung injury and air leak that did not spontaneously close, iatrogenic lung injury (e.g. due to central venepuncture) and mechanical positive-pressure ventilation.

TABLE 29.3 The 'deadly dozen' threats to life from chest injury.

Immediately life-threatening	• Airway obstruction • Tension pneumothorax • Pericardial tamponade • Open pneumothorax • Massive haemothorax • Flail chest
Potentially life-threatening	• Aortic injuries • Tracheobronchial injuries • Myocardial contusion • Rupture of the diaphragm • Oesophageal injuries • Pulmonary contusion

The clinical presentation is dramatic. The patient is increasingly restless with tachypnoea, dyspnoea and distended neck veins (similar to pericardial tamponade). Clinical examination may reveal tracheal deviation; this is a late finding and is not necessary to clinically confirm diagnosis. There will also be hyper-resonance and decreased or absent breath sounds over the affected hemithorax. Tension pneumothorax is a clinical diagnosis and treatment should never be delayed by waiting for radiological confirmation. Always treat it with a high index of suspicion of being present (*Figure 29.3*).

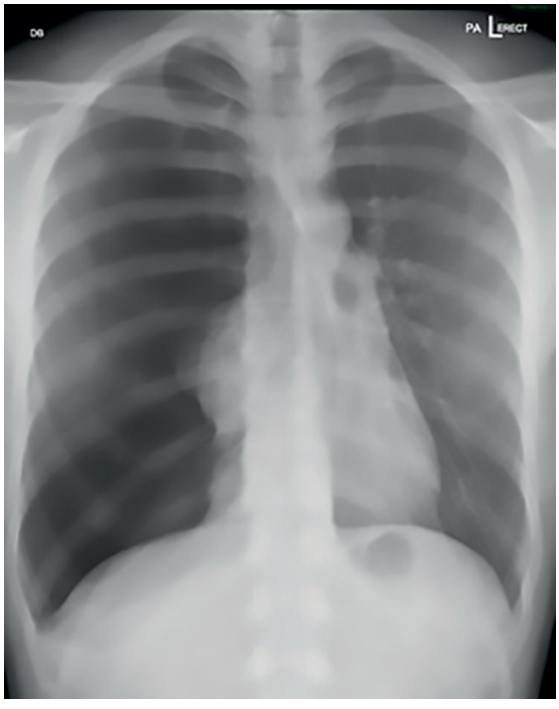

Figure 29.3 Radiological appearance of a tension pneumothorax (courtesy of Dr Elizabeth Dick, Consultant Radiologist, Imperial College Healthcare NHS Trust, London, UK).

Treatment consists of immediate decompression. This was historically taught by rapid insertion of a large-bore cannula into the second intercostal space in the mid-clavicular line of the affected side, followed by insertion of a chest tube through the fifth intercostal space in the anterior axillary line. However, current teaching advocates undertaking decompression in the safe triangle – defined posteriorly by latissimus dorsi, anteriorly by the lateral border of pectoralis major and inferiorly by a line perpendicular to the nipple going to the back, just anterior to the mid-axillary line – or, in extremis, a finger thoracostomy at the same location.

Pericardial tamponade

Pericardial tamponade needs to be differentiated from a tension pneumothorax in the shocked patient with distended neck veins. It is most commonly the result of penetrating trauma. Accumulation of a relatively small amount of blood (50 mL) into the non-distensible pericardial sac can produce compression of the heart and obstruction of the venous return, leading to decreased filling of the cardiac chambers during diastole. All patients with penetrating injury anywhere near the heart plus shock must be considered to have a cardiac injury until proven otherwise. Classically, the presentation consists of central venous pressure elevation, a decline in arterial pressure with tachycardia and muffled heart sounds. However, in cases

in which major bleeding from other sites has taken place, the neck veins may be flat. A high index of suspicion and further diagnostic investigations will be needed to make the diagnosis is those cases that are not clinically obvious. These include an eFAST showing fluid in the pericardial sac, which is the most expeditious and reliable diagnostic tool, or chest radiography, looking for an enlarged heart shadow.

In penetrating injury to the heart there is usually a substantial clot in the pericardium, which may prevent aspiration. **Pericardiocentesis has no role in the management of cardiac tamponade secondary to penetrating myocardial injury**. The correct immediate treatment of tamponade is operative, either via a subxiphoid window or by open surgery (sternotomy or left anterolateral thoracotomy), with repair of the heart in the operating theatre if time allows or otherwise in the emergency department.

Summary box 29.4

Pericardial tamponade

- The presentation is similar to a tension pneumothorax – deteriorating cyanosis, tachycardia and agitation
- eFAST is diagnostic and may also detect free fluid in the abdomen or pericardium
- There is no role for pericardiocentesis in traumatic cardiac tamponade. A left anterolateral thoracotomy or sternotomy should be performed with evacuation of the haematoma and repair of the myocardium

Open pneumothorax ('sucking chest wound')

This is due to a large open defect in the chest (>3 cm), leading to immediate equilibration between intrathoracic and atmospheric pressure. If the opening in the chest wall exceeds about two-thirds of the diameter of the trachea, then with each inspiratory cycle air will be preferentially drawn through the defect rather than through the trachea. Air accumulates in the hemithorax (rather than in the lung) with each inspiration, leading to profound hypoventilation on the affected side and hypoxia. If there is a valvular effect, increasing amounts of air in the pleura will result in a tension pneumothorax (see ***Tension pneumothorax***).

Initial management consists of promptly closing the defect with a sterile occlusive plastic dressing (e.g. OPSITE◊ or similar product), taped on three sides to act as a flutter-type valve. A chest tube is inserted as soon as possible in a site remote from the injury site.

Massive haemothorax

The most common cause of massive haemothorax in blunt injury is continuing bleeding from torn intercostal vessels or occasionally from the internal mammary artery secondary to fractures of the ribs. In penetrating injury, a variety of viscera, both thoracic and abdominal (with blood leaking through a hole in the diaphragm from the positive pressure abdomen into the negative pressure thorax), may be involved.

Accumulation of blood in a haemothorax can significantly compromise respiratory efforts, compressing the lung and preventing adequate ventilation. Presentation is with haemorrhagic shock, flat neck veins, unilateral absence of breath sounds and dullness to percussion. The initial treatment consists of correcting the hypovolaemic shock, insertion of an intercostal drain and, in some cases, intubation. Initial drainage of more than 1500 mL of blood or ongoing haemorrhage of more than 200 mL/h over 3–4 hours is generally considered an indication for urgent thoracotomy.

Blood in the pleural space should be removed as completely and rapidly as possible to prevent ongoing bleeding, an empyema or fibrothorax later. **There is no role for clamping a chest tube to tamponade a massive haemothorax**.

The following points are important in the management of an open pneumothorax/haemothorax:

- if the lung does not reinflate, the drain should be placed on low-pressure (5 cmH_2O) suction;
- clot occlusion of a chest drainage tube may result in 'no' drainage, even in the presence of ongoing bleeding;
- a second drain is sometimes necessary (but see ***Tracheobronchial injuries***);
- a chest radiograph or eFAST can help identify the presence of blood;
- physiotherapy and active mobilisation should begin as soon as possible.

Flail chest

This condition usually results from blunt trauma associated with multiple rib fractures, and is defined as three or more ribs fractured in two or more places. The blunt force typically also produces an underlying pulmonary contusion. The diagnosis is made clinically in patients who are not ventilated, not by radiography. To confirm the diagnosis the chest wall can be observed for paradoxical motion of a chest wall segment. On inspiration, the loose segment of the chest wall is displaced inwards and therefore less air moves into the lungs. On expiration, the segment moves outwards (paradoxical respiration). Voluntary splinting of the chest wall occurs as a result of pain, so mechanically impaired chest wall movement and the associated lung contusion all contribute to the hypoxia. There is a high risk of developing a pneumothorax or haemothorax. The CT scan remains the gold standard for diagnosis of this condition.

Traditionally, mechanical ventilation was used to 'internally splint' the chest but had a price in terms of intensive care unit (ICU) resources and ventilation-dependent morbidity. Currently, treatment consists of oxygen administration, adequate analgesia (including opiates) and physiotherapy. If a chest tube is in place, topical intrapleural local analgesia introduced via the tube can also be used. Ventilation is reserved for patients developing respiratory failure despite adequate analgesia and oxygen. Surgery to stabilise the flail segment using internal fixation of the ribs may be useful in a selected group of patients with isolated or severe chest injury and pulmonary contusion.

◊ Trademark of Smith+Nephew.

Figure 29.4 Chest radiograph showing a widened mediastinum (courtesy of Dr Elizabeth Dick, Consultant Radiologist, Imperial College Healthcare NHS Trust, London, UK).

Figure 29.5 Computed tomography scan showing aortic disruption (courtesy of Dr Elizabeth Dick, Consultant Radiologist, Imperial College Healthcare NHS Trust, London, UK).

Potentially life-threatening injuries

Thoracic aortic disruption

Traumatic aortic rupture is a common cause of sudden death after a vehicle collision or fall from a great height. The vessel is relatively fixed distal to the ligamentum arteriosum, just distal to the origin of the left subclavian artery. The shear forces from a sudden impact disrupt the intima and media. If the adventitia is intact, the patient may remain physiologically non-compromised.

Thoracic aortic injury should be clinically suspected in patients with gross asymmetry in systolic blood pressure (between the two upper limbs, or between upper and lower limbs), widened pulse pressure and chest wall contusion. Erect chest radiography can also suggest thoracic aortic disruption, the most common radiological finding being a widened mediastinum (***Figure 29.4***). The diagnosis is confirmed by a CT scan of the mediastinum (***Figure 29.5***). In the hypotensive patient, widening of the mediastinum and aortic injury is not the cause of the hypotension. Invariably, these patients have other injuries causing hypotension as patients with complete aortic disruption rarely, if ever, survive to reach hospital.

In the presence of thoracic aortic injury, initial management consists of control of the systolic arterial blood pressure (to less than 120 mmHg). Thereafter, an endovascular intra-aortic stent (***Figure 29.6***) can be placed, or the tear can be operatively repaired by direct repair or by excision and grafting using a Dacron graft.

Tracheobronchial injuries

Severe subcutaneous emphysema with respiratory compromise can suggest tracheobronchial disruption. A chest drain placed on the affected side will reveal a large air leak and the collapsed lung may fail to re-expand. Bronchoscopy is diagnostic. Treatment involves intubation of the unaffected bronchus followed by operative repair. Referral to a trauma centre is advised.

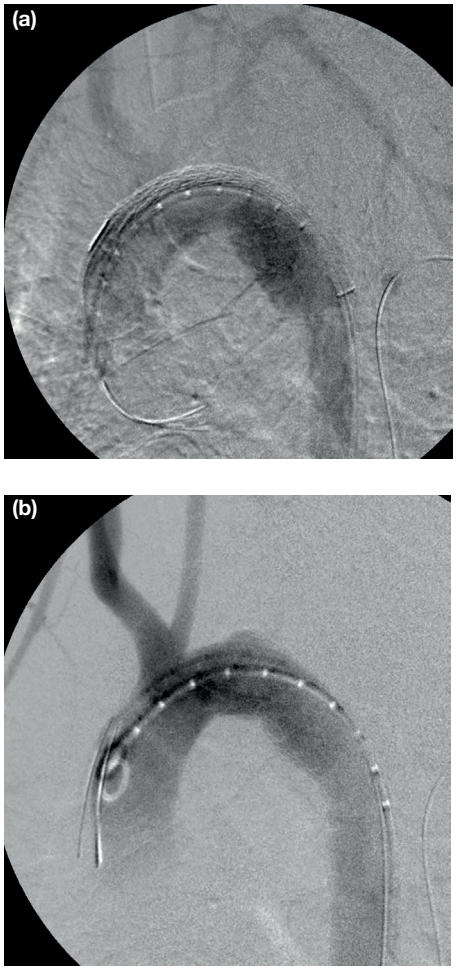

Figure 29.6 (a) Aortic tear showing the presence of a preinflation stent and test run. (b) Aortic tear post inflation of the stent and test run (courtesy of Dr Elizabeth Dick, Consultant Radiologist, Imperial College Healthcare NHS Trust, London, UK).

Blunt myocardial injury

Significant blunt cardiac injury that causes haemodynamic and physiological instability is rare. Blunt myocardial injury should be suspected in any patient sustaining blunt trauma who develops early electrocardiogram abnormalities.

Transthoracic echocardiography may show wall motion abnormalities. A transoesophageal echocardiogram may also be helpful. There is very little evidence that enzyme estimations have any place in diagnosis.

All patients with myocardial contusion diagnosed with conduction abnormalities are at risk of developing sudden dysrhythmias and should be closely monitored.

Diaphragmatic injuries

Any penetrating injury below the fifth intercostal space should raise suspicion of diaphragmatic penetration and, therefore, injury to abdominal contents.

Blunt injury to the diaphragm is usually caused by a compressive force applied to the torso. The diaphragmatic rupture is usually large, with herniation of the abdominal contents into the chest. Diagnosis of diaphragmatic rupture can easily be missed in the acute phase, and may only be discovered at operation or through the presentation of complications.

Most diaphragmatic injuries are silent and the presenting features are those of injury to the surrounding organs. There is no single standard investigation. Historically and in limited resource environments, chest radiography after placement of a nasogastric tube may be helpful (as this may show the stomach herniated into the chest). CT scan and ultrasound scan all lack positive or negative predictive value. The most accurate evaluation is by video-assisted thoracoscopy or laparoscopy, the latter offering the advantage of allowing the surgeon to proceed to a repair and additional evaluation of the abdominal organs.

The thorax is at negative pressure and the abdomen is at positive pressure. A complication of a breach of the diaphragm is herniation of abdominal contents into the chest. This may present much later, and strangulation of any of the contents can then occur, with a high mortality rate. Operative repair is recommended in all cases. All penetrating diaphragmatic injury must be repaired via the abdomen – and not the chest – to rule out penetrating hollow viscus injury.

Oesophageal injury

Most oesophageal injuries result from penetrating trauma; blunt injury is rare but should be suspected in patients exposed to barotrauma. A high index of suspicion is required. The patient can present with odynophagia (pain on swallowing saliva, foods or fluids), subcutaneous or mediastinal emphysema, pleural effusion, air in the perioesophageal space and unexplained fever. Mediastinal and deep cervical emphysema are evidence of an aerodigestive injury until proven otherwise.

The mortality rate rises exponentially if treatment is delayed. A combination of CT with oral contrast and oesophagoscopy confirms the diagnosis in the great majority of cases. The treatment is operative repair of any defect and drainage.

Pulmonary contusion

Pulmonary contusion occurs more frequently following blunt trauma, and is usually associated with a flail segment or fractured ribs. This is a very common, potentially lethal injury and the major cause of hypoxaemia after blunt trauma. Following gunshot wounds, there is an area of contusion from the shock wave of the bullet.

The natural progression of pulmonary contusion is worsening hypoxaemia for the first 24–48 hours. Chest radiographic findings may be typically delayed. Contrast CT scanning can be confirmatory. Haemoptysis or blood in the endotracheal tube is a sign of pulmonary contusion. In mild contusion, the treatment is oxygen administration, pulmonary toilet and adequate analgesia. In more severe cases mechanical ventilation is necessary. Normovolaemia is critical for adequate tissue perfusion and fluid restriction is not advised.

EMERGENCY THORACIC SURGERY

Emergency thoracic surgery is an essential part of the armamentarium of any surgeon dealing with major trauma. A timely surgical intervention for the correct indications can be the key step in saving an injured patient's life.

It is important to make a distinction between:

- immediate thoracotomy in the emergency department for the control of haemorrhage, cardiac tamponade or internal cardiac massage;
- emergency sternotomy for anterior mediastinal structures and the heart;
- planned thoracotomy for definitive correction of the problem – this usually takes place in the more controlled environment of the operating theatre.

The clinical decision as to whether a patient requires surgery in the emergency department or they can be transferred to the operating theatre can be complex. It is far better to perform a thoracotomy in the operating theatre, either through an anterolateral approach or a median sternotomy, with good light and assistance and the potential for autotransfusion or bypass, than it is to attempt heroic emergency surgery in the resuscitation area. However, if the patient is *in extremis* with a falling systolic blood pressure, there is no choice but to proceed immediately with a left anterolateral thoracotomy. In certain circumstances, when care is futile, it may not need to be performed at all. A resuscitation room thoracotomy following blunt trauma has limited indications and is rarely successful.

Emergency department thoracotomy or sternotomy

Emergency department thoracotomy (EDT) should be reserved for those patients with penetrating injury in whom signs of life are still present. Patients who have received cardiopulmonary resuscitation (CPR) in the prehospital phase of their care are unlikely to survive, and electrical activity must be present.

In certain situations, EDT is considered futile:

- CPR for more than 15 minutes (despite endotracheal intubation) in the presence of penetrating thoracic trauma;
- CPR for more than 10 minutes (despite endotracheal intubation) in the presence of blunt thoracic trauma;
- blunt trauma when there have been no signs of life at the scene.

The survival rates for EDT in patients with penetrating trauma in whom the blood pressure is falling despite adequate resuscitation are shown in *Table 29.4*.

TABLE 29.4 Survival rates for thoracotomy in patients with penetrating trauma.

Blood pressure despite resuscitation	Survival
>60 mmHg	60%
>40 mmHg	30%
<40 mmHg	3%

The aim of EDT is to perform:

- internal cardiac massage in the cardiovascularly 'full' patient (no role for internal massage in the 'empty' patient);
- control of haemorrhage from injury to the heart or lung;
- control of intrathoracic haemorrhage from other sources;
- control of massive air leak;
- clamping of the thoracic aorta to preserve the blood supply to the heart and brain, and cutting off the arterial supply distally, in a moribund patient with a major distal penetrating injury.

Planned emergency thoracotomy

Planned emergency thoracotomy implies an emergency thoracotomy performed as a planned procedure in the operating theatre, directed at the management of a specific injury. As such, the approach chosen is dependent on the indication for surgery and the organ injured (*Table 29.5*). Some organs are best approached through a median sternotomy. Otherwise the thoracotomy may be right or left sided, and these may be joined, producing the so-called 'clamshell incision'. This gives excellent exposure for any surgeon who is not routinely entering the chest.

Posterolateral thoracotomy is not used in the emergency situation because of the difficulties in positioning of the patient, except for specific access to certain posterior mediastinal organs.

TABLE 29.5 Different approaches to the contents of the chest cavity.

Approach	Best for
Left anterolateral thoracotomy	• Left lung and lung hilum • Thoracic aorta • Origin of left subclavian artery • Left side of heart • Lower oesophagus
Right anterolateral thoracotomy	• Right lung and lung hilum • Azygos veins • Superior vena cava • Infracardiac inferior vena cava • Upper oesophagus • Thoracic trachea
Median sternotomy	• Anterior aspect of heart • Anterior mediastinum • Ascending aorta and arch of aorta • Pulmonary arteries • Carina of the trachea

ABDOMINAL INJURY

Patients who have suffered abdominal trauma can generally be classified into the following categories based on their physiological condition after initial resuscitation:

- physiologically 'normal' – investigation can be completed before treatment is planned;
- physiologically 'non-compromised' – investigation is more limited; it is aimed at establishing whether the patient can be managed non-operatively, whether angioembolisation can be used or whether surgery is required;
- physiologically 'compromised' – investigations need to be suspended as immediate surgical correction of the bleeding is required.

A trauma laparotomy is the final step in the pathway to delineate intra-abdominal injury. Occasionally it is difficult to determine the source of bleeding in the shocked, multiple injured patient. If doubt still exists, especially in the presence of other injuries, a laparotomy may still be the safest option. The key is to make a decision, as indecision leads to delay in definitive control.

The patient's physiology must be assessed constantly; if there is an indication that the patient is still actively bleeding, the source must be identified unless the patient is unstable and requires immediate surgery. Blood loss into the abdomen can be subtle and there may be no clear clinical signs. Blood is not an irritant and does not initially cause any abdominal pain. Distension is subjective, and a drop in the blood pressure may be a very late sign in a young fit patient. Examination in compromised patients should take place either in the emergency department or in the operating theatre if the patient is deteriorating rapidly.

Investigation

Investigations are driven by the cardiovascular status of the patient. In torso trauma, the best and most sensitive modality is a CT scan with intravenous contrast; however, in the unstable patient, this is generally not possible.

In patients with penetrating injury, metal markers (e.g. bent paper clips) should be placed on all external wounds before plain films are taken, irrespective of the area being radiographed, as this allows an assessment of the trajectory and helps to correlate the number of holes and the number of missiles that can be seen within the patient. This will help determine whether two holes are indicative of one missile passing through the patient, or two missiles, both retained internally (*Figure 29.7*). A single hole implies that the projectile has been retained.

Focused abdominal sonography for trauma and extended FAST (FAST and eFAST)

Focused abdominal sonography for trauma (FAST) is a technique whereby ultrasound (sonography) imaging is used to assess the torso for the presence of free fluid in the abdominal cavity, and is extended into the thoracic cavities and pericardium (eFAST). There should be no attempt to determine the nature or extent of the specific injury. eFAST is usually a

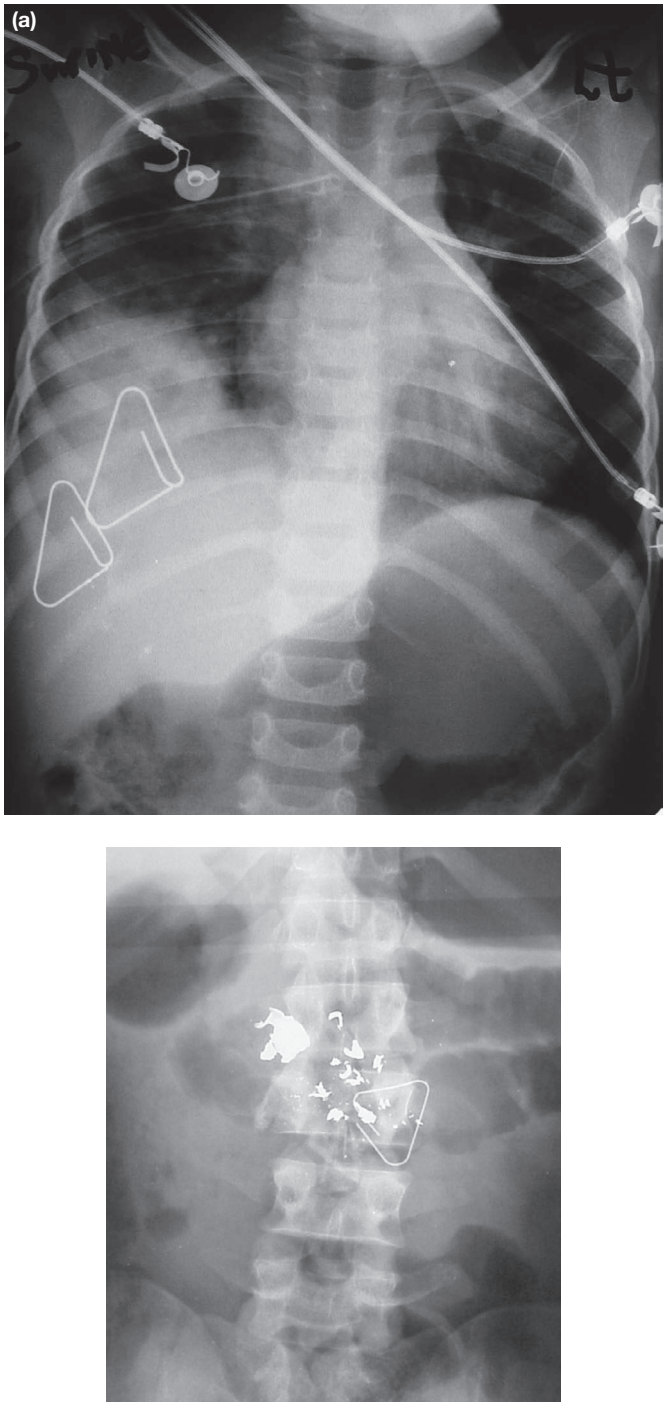

Figure 29.7 (a) Chest radiograph showing a gunshot wound with bullet markers. **(b)** Abdominal radiograph of a gunshot wound showing bullet markers.

rapid, reproducible, portable and non-invasive bedside test and can be performed at the same time as resuscitation. eFAST is accurate at detecting >100 mL of free blood; however, it is very operator dependent and, especially if the patient is very obese or the bowel is full of gas, it may be unreliable. Hollow viscus injury and solid organ injury are difficult to diagnose, even in experienced hands, as small amounts of gas or fluid are difficult to assess and eFAST has a low sensitivity (29–35%) for organ injury without haemoperitoneum. eFAST is also unreliable for excluding injury in penetrating trauma. If there is doubt, the eFAST examination can be repeated.

Summary box 29.5

Utilisation of eFAST

- Detects free fluid in the abdomen or pericardium
- Will not reliably detect less than 100 mL of free blood
- Does not directly identify injury to hollow viscus
- Cannot reliably exclude injury in penetrating trauma
- May need repeating or supplementing with other investigations
- Is unreliable for assessment of the retroperitoneum

Diagnostic peritoneal lavage

Diagnostic peritoneal lavage (DPL) is a test rarely used in modern-day practice but can be of value in resource-limited settings. It is a test used to assess the presence of blood or contaminants in the abdomen. A nasogastric tube is placed to empty the stomach and a urinary catheter is inserted to drain the bladder.

A cannula is inserted below the umbilicus, directed caudally and posteriorly. The cannula is aspirated for blood (>10 mL is deemed as positive) and, following this, 500 mL of warmed Ringer's lactate solution is allowed to run into the abdomen from a 1-litre bag. The bag, with 500 mL remaining, is placed on the floor and the intra-abdominal fluid is allowed to flow under the influence of gravity – this aids drainage. The presence of frank blood or similar contents to a nasogastric tube or urinary catheter denotes a positive DPL. If time allows and laboratory diagnosis is available, the presence of >100 000 red cells/μL or >500 white cells/μL is deemed positive (this is equivalent to 20 mL of free blood in the abdominal cavity), as is a raised amylase level. In the absence of laboratory facilities, a urine dipstick may be useful. Drainage of lavage fluid via a chest drain indicates penetration of the diaphragm.

Although DPL has largely been replaced by eFAST (see ***Focused abdominal sonography for trauma and extended FAST (FAST and eFAST)***), it remains the standard in many institutions where eFAST is not available or is unreliable.

Computed tomography scan

CT has become the 'gold standard' for the intra-abdominal diagnosis of injury in the stable patient. The scan can be performed using intravenous contrast. CT is sensitive for blood and individual organ injury as well as for retroperitoneal injury. An entirely normal abdominal CT is usually sufficient to exclude intraperitoneal injury.

The following points are important when performing CT:

- it remains an inappropriate investigation for physiologically compromised patients;

Sydney Ringer, 1835–1910, Professor of Clinical Medicine, University College Hospital, London, UK.

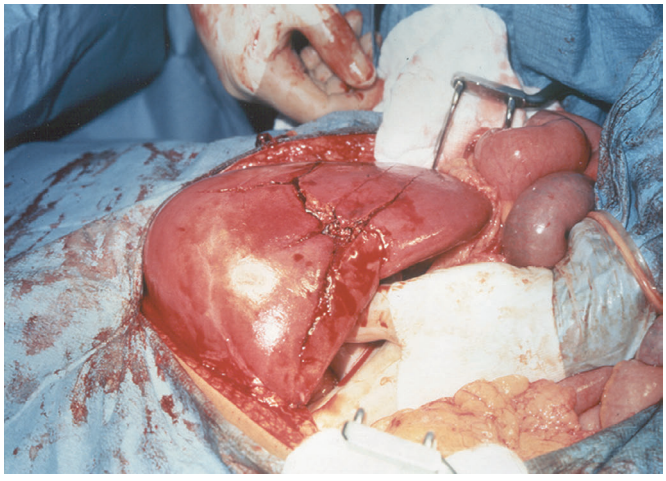

Figure 29.8 Compression injury to the liver, bursting the liver substance.

- if duodenal injury is suspected from the mechanism of injury, oral contrast may be helpful;
- if rectal and distal colonic injury is suspected in the absence of blood on rectal examination, air around the colon may indicate injury; in all cases clinical suspicion supersedes investigation results.

Laparoscopy

Laparoscopy or thoracoscopy may be a valuable screening investigation in physiologically non-compromised patients with penetrating trauma to detect or exclude peritoneal penetration and/or diaphragmatic injury.

Laparoscopy may be divided into:

- screening: used to exclude a penetrating injury with breach of the peritoneum;
- diagnostic: finding evidence of injury to viscera;
- therapeutic: used to repair the injury.

In most institutions, evidence of penetration requires a laparotomy to evaluate organ injury as it is difficult to exclude all intra-abdominal injuries laparoscopically. When used in this role laparoscopy reduces the non-therapeutic laparotomy rate. There is no place for laparoscopy in the unstable patient.

INDIVIDUAL ORGAN INJURY

Liver

Blunt liver trauma occurs as a result of direct injury. The liver is a solid organ and compressive forces can easily burst the liver substance (***Figure 29.8***). The liver is usually compressed between the impacting object and the ribcage or vertebral column. Most injuries are relatively minor and can be managed non-operatively.

Penetrating trauma to the liver is relatively common. Bullets have a shock wave and when they pass through a solid structure such as the liver they cause significant damage some distance from the actual track of the bullet. Not all penetrating wounds require operative management and may stop bleeding spontaneously.

In the physiologically non-compromised patient, CT is the investigation of choice. It provides information on the liver injury itself, as well as on injuries to the adjoining major vascular and biliary structures. Injury in which there is a suggestion of a vascular component should be reimaged, as there is a significant risk of the development of subsequent ischaemia, false aneurysms, arteriovenous fistulae or haemobiliary fistula. It is advised that all patients should be rescanned prior to discharge.

Liver injury can be graded and managed using the American Association for the Surgery of Trauma (AAST) Injury Scoring Scale (ISS) (https://www.aast.org/resources-detail/injury-scoring-scale).

Management

The operative management of liver injuries can be summarised as 'the four Ps':

- Pressure;
- Pringle;
- Plug;
- Pack.

At laparotomy the liver is reconstituted and bleeding is controlled by direct bimanual compression to achieve its normal architecture as best as possible (Pressure). The inflow from the portal triad is controlled by a Pringle's manoeuvre, with direct compression of the portal triad, either digitally or using a soft clamp (***Figure 29.9***). This has the effect of reducing arterial and portal venous inflow into the liver, although it does not control the backflow from the inferior vena cava and hepatic veins. Any holes due to penetrating injury can be plugged directly using silicone tubing or a Sengstaken–Blakemore tube; after controlling any arterial bleeding, the liver can then be packed (see ***Damage control surgery***).

Bleeding points should be controlled locally when possible, and such patients, if required, subsequently undergo angioembolisation. It is not usually necessary to suture penetrating injuries of the liver unless haemostasis cannot be controlled by other means. If there has been direct damage to the hepatic artery, it can be tied off. Damage to the portal vein must be repaired, as tying off the portal vein carries a greater than 50% mortality rate. If it is not technically feasible to repair the vein at the time of surgery, it should be shunted and the patient referred to a specialist centre. A drainage system must be left *in situ* following hepatic surgery. Finally, the liver can be definitively packed, restoring the anatomy as closely as possible. Placing omentum into cracks in the liver is not recommended.

James Hogarth Pringle, 1863–1941, Australian-born surgeon, The Royal Infirmary, Glasgow, UK.
Robert William Sengstaken, 1923–1978, surgeon, Garden City, NY, USA, and **Arthur Hendley Blakemore**, 1897–1970, Associate Professor of Surgery, The College of Physicians and Surgeons, Columbia University, New York, NY, USA, designed a tube with two in-built balloons for the treatment of oesophageal varices. The tube was passed and the distal balloon inflated. The tube was drawn backwards until the distal balloon was held at the oesophageal hiatus. The proximal balloon was inflated, allowing tamponade of any varices in the distal oesophagus.

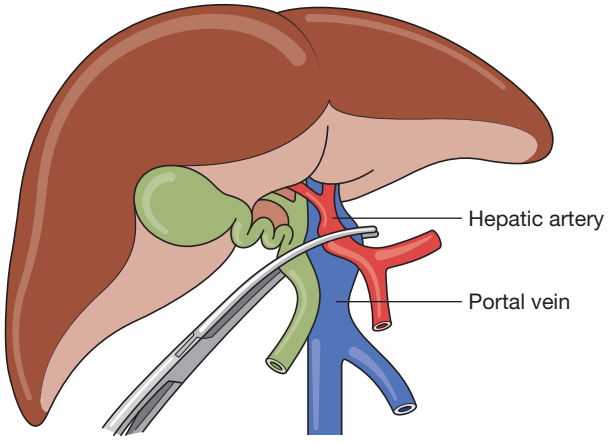

Figure 29.9 The Pringle manoeuvre.

Summary box 29.6

Liver trauma

- Blunt trauma occurs as the result of direct compression
- Penetrating trauma of the upper abdomen or lower thorax can damage the liver
- CT scanning is the investigation of choice in a stable patient
- Surgical management consists of: Pressure, Pringle, Plug and Pack
- The hepatic artery can be tied off but not the portal vein (which should be stented)
- Closed drainage should always be used

Biliary injuries

Isolated traumatic biliary injuries are rare and occur mainly from penetrating trauma, often in association with injuries to other structures that lie in close proximity. The common bile duct can be repaired over a T-tube or drained and referred to appropriate care as part of damage control, or even ligated.

Spleen

Splenic injury occurs from direct blunt trauma. Most isolated splenic injuries, especially in children, can be managed non-operatively. However, in adults, especially in the presence of other injury or physiological compromise, laparotomy should be considered. The spleen can be theoretically packed, repaired or placed in a mesh bag. However, in reality, splenectomy is the safer option, especially in the compromised patient with multiple potential sites of bleeding. In certain situations, selective angioembolisation of the spleen can play a role.

Following splenectomy there are significant, though transient, changes to blood physiology. The platelet and white count rise and may mimic sepsis. Inoculation against *Pneumococcus* is advisable within 2–3 weeks, by which time the patient's immune system has recovered.

Pancreas

Most pancreatic injury occurs as a result of blunt trauma. The major problem is that of diagnosis because the pancreas is a retroperitoneal organ. CT remains the mainstay of accurate diagnosis. Amylase or lipase estimation is insensitive. In penetrating trauma, injury may only be detected during laparotomy.

Classically the pancreas should be treated with conservative surgery and closed, low-suction drainage. Injuries are treated according to the ISS system of the AAST. Injuries to the pancreatic body to the left of the superior mesenteric vessels and to the tail are treated by closed drainage alone, with distal pancreatectomy if the duct is involved. Proximal injuries (to the right of the superior mesenteric artery) are treated as conservatively as possible, although partial pancreatectomy may be necessary. The role of pyloric exclusion remains controversial and remains surgeon dependent. A Whipple's procedure (pancreaticoduodenectomy) is rarely needed and should not be performed in the emergency situation because of the very high associated mortality rate. A damage control procedure with packing and drainage should be performed and the patient referred for definitive surgery once stabilised.

Stomach

Most stomach injuries are caused by penetrating trauma. Blood presence is diagnostic if found in the nasogastric tube, in the absence of bleeding from other sources. Surgical repair is required but great care must be taken to examine the stomach fully, as an injury to the front of the stomach can be expected to have an 'exit' wound elsewhere on the organ.

Duodenum

Duodenal injury is frequently associated with injuries to the adjoining pancreas. Like the pancreas, the duodenum lies retroperitoneally and so injuries are hidden, discovered late or at laparotomy performed for other reasons. CT is the diagnostic modality of choice. The only sign may be gas or a fluid collection in the periduodenal tissue, and leakage of oral contrast, administration of which may improve accuracy of diagnosis.

Smaller injuries can be repaired primarily. The first, third and fourth parts of the duodenum behave like small bowel and can be repaired in the same fashion. The second part of the duodenum is fixed to the head of the pancreas with a common blood supply and may have a poorer blood supply than the remainder. Major trauma, especially if the head of the pancreas is simultaneously injured, should be treated as part of a damage control procedure and be referred for definitive care.

Small bowel

The small bowel is frequently injured as a result of blunt trauma. The individual loops may be trapped, causing high-pressure rupture of a loop or tearing of the mesentery. Penetrating trauma is also a common cause of injury.

Allen Oldfather Whipple, 1881–1963, Valentine Mott Professor of Surgery, The College of Physicians and Surgeons, Columbia University, New York, NY, USA.

Small bowel injuries need urgent repair. Haemorrhage control takes priority and these wounds can be temporarily controlled with simple sutures. In blunt trauma with mesenteric vessel damage, the bowel ischaemia that results will dictate the extent of a resection. Resections should be carefully planned to limit the loss of viable small bowel, but should be weighed against an excessive number of repairs or anastomoses. Haematomas in the small bowel mesenteric border need to be explored to rule out perforation. With low-energy wounds, primary repair can be performed, whereas more destructive wounds associated with military-type weapons require resection and anastomosis. Damage control 'clip and drop' of damaged or resected bowel may be necessary.

Colon

Blunt injuries to the colon are relatively infrequent; penetrating injuries occur more often. If relatively little contamination is present and the viability is satisfactory, such wounds can be repaired primarily. If, however, there is extensive contamination, the patient is physiologically compromised or the bowel is of doubtful viability, then the bowel can be closed off ('clip and drop'). A defunctioning colostomy can be formed later or the bowel reanastomosed once the patient is stable.

Rectum

Approximately 5% of colon injuries involve the rectum. These are generally from a penetrating injury, although occasionally the rectum may be damaged following fracture of the pelvis. Digital rectal examination will reveal the presence of blood, which is evidence of intestinal or rectal injury. These injuries are often associated with bladder and proximal urethral injury.

With intraperitoneal injuries, the rectum is managed as for colonic injuries. Full-thickness extraperitoneal rectal injuries can be managed with primary repair and drainage depending on the type of injury, i.e. suitable for knife wounds but not ballistic trauma. Where there is extensive tissue loss, this should be managed with either a diverting end-colostomy and closure of the distal end (Hartmann's procedure) or a loop colostomy. Presacral drainage is no longer used.

Renal and urological tract injury

In physiologically non-compromised patients, CT scanning with contrast is the investigation of choice. For assessment of bladder injury a cystogram should be performed at the time of CT. A minimum of 300 mL of contrast is instilled into the bladder via a urethral catheter. The large volume is essential because a small volume may not distend the bladder enough to produce a leak from a small bladder injury, once the cystic muscle is contracted.

Generally, renal injury is managed non-operatively unless the patient is physiologically compromised. The kidney can be angioembolised if required.

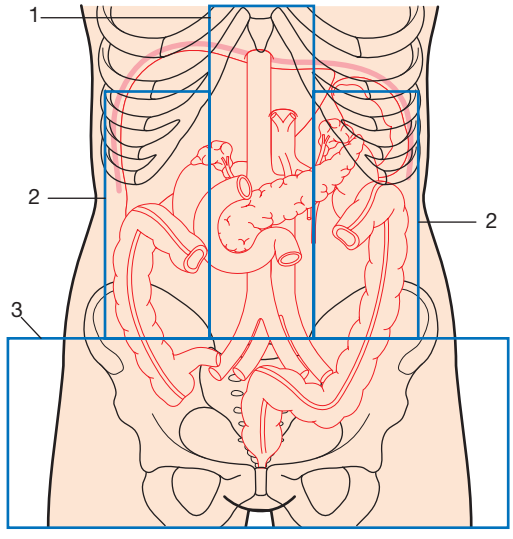

Figure 29.10 The zones of the retroperitoneum. Zone 1, central; zone 2, lateral; zone 3, pelvic.

Ureteric injury is rare and is generally due to penetrating trauma. Most ureters can be repaired or diverted if necessary, or may even be ligated as part of damage control procedures.

Intraperitoneal rupture of the bladder, usually from direct blunt injury, will require surgical repair. Extraperitoneal rupture is usually associated with a fracture of the pelvis and will heal with adequate urine drainage via the transurethral route. Suprapubic drainage is reserved for when this is not possible.

Summary box 29.7

Injuries to structures in the abdomen

- In children, splenic injury can be managed non-operatively in most cases, but not if physiologically compromised
- Duodenal injuries are often associated with pancreatic trauma
- Bowel injuries need urgent definitive repair, or isolation using resection or by stapling
- Rectal injuries are managed depending on whether intra- or extraperitoneal
- Kidney and urinary tract injuries are best diagnosed with contrast CT scanning
- Intraperitoneal bladder tears need formal repair and drainage

Retroperitoneum

Injury to the retroperitoneum is often difficult to diagnose, especially in the presence of other injury, when the signs may be masked. Diagnostic tests (such as ultrasound and DPL) may be negative. The best diagnostic modality is CT, but this requires a physiologically stable patient. The retroperitoneum is divided into three zones (*Figure 29.10*) for the purposes of intraoperative management in blunt trauma:

Henri Albert Charles Antoine Hartmann, 1860–1952, Professor of Clinical Surgery, Faculty of Medicine, University of Paris, Paris, France.

- Zone 1 (central): central haematomas should always be explored, once proximal and distal vascular control has been obtained.
- Zone 2 (lateral): lateral haematomas should only be explored if they are expanding or pulsatile or penetrating injury is present. They are usually renal in origin and can be managed non-operatively, although they may sometimes require angioembolisation.
- Zone 3 (pelvic): as with zone 2, these should only be explored if they are expanding or pulsatile or penetrating injury is present. Pelvic haematomas are exceptionally difficult to control and, whenever possible, should not be opened; they are best controlled with compression or-extraperitoneal packing, or, if the bleeding is arterial in origin, with angioembolisation.

THE PELVIS

Although mortality following severe pelvic fractures has decreased dramatically with better methods of controlling haemorrhage, these patients still represent a significant challenge to every link of the treatment chain. Mortality rates exceeding 40% have recently been reported. Further, pelvic bleeding as one of the 'hidden bleeding sources' is still underestimated or missed, as retrospective chart analyses of potentially preventable deaths have revealed. Extreme force is required to disrupt the pelvic ring, and associated injuries and extrapelvic bleeding sources are common (up to 50% of cases). The haemodynamically unstable patient with severe pelvic fracture has a 90% risk of associated injuries and a 30% risk of intra-abdominal bleeding.

To save these patients, three questions need to be addressed:

- Is the patient at high risk of massive bleeding?
- Where is the source of the bleeding?
- How to stop the bleeding?

Anatomy

The surgical anatomy of the pelvis is key to the understanding of pelvic injuries.

- The pelvic inlet is circular. It is a structure that is immensely strong, but routinely gives way at more than one point should sufficient force be applied to it. Therefore, isolated fractures of the anterior or posterior pelvic ring are uncommon.
- The forces required to fracture the pelvic ring do not respect the surrounding organ systems.
- The pelvis has a rich collateral blood supply, especially across the sacrum and posterior part of the ileum. The cancellous bone of the pelvis also has an excellent blood supply. Most pelvic haemorrhage emanates from venous injury and fracture sites. However, in the haemodynamically unstable patient with severe pelvic injury, arterial bleeding is more frequent. Important for the treatment is that the surgeon has to deal with both arterial and venous bleeding.

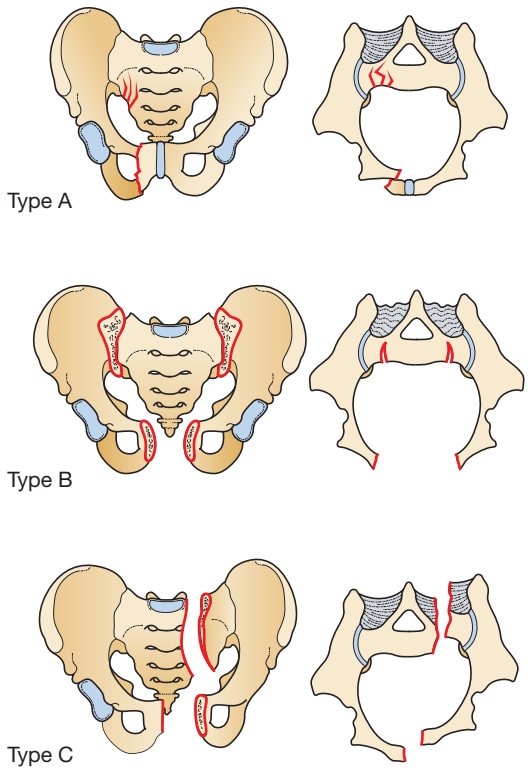

Figure 29.11 Tile classification of fractures of the pelvis.

- Postmortem examination has shown that the extrapelvic peritoneal space can accommodate more than 3000 mL. However, in the case of a severe pelvic fracture where the retroperitoneal compartment is disrupted and the external bony barrier is not stable, haematoma may extend upwards towards the mediastinum ('chimney effect') or downwards into the medial thigh in case of rupture of the pelvic floor.
- All iliac vessels, the sciatic nerve roots (including the lumbosacral nerve) and the ureters cross the sacroiliac joint; disruption of this joint may cause severe haemorrhage and sometimes cause arterial obstruction of the internal iliac artery and sciatic nerve palsy. Injuries to the ureters are rare.
- The pelvic viscera are suspended from the bony pelvis by condensations of the endopelvic fascia. Shear forces acting on the pelvis will transmit these to pelvic viscera, leading to avulsion and shearing injuries.
- The pelvis also includes the acetabulum, a major structure in weight transfer to the leg. Inappropriate treatment will lead to severe disability.

Classification

Pelvic ring fractures can be classified into three types, using the Tile classification (for subtypes and other classifications see ***Further reading***), based on the severity of the fracture (and reflecting the energy required to cause it) (***Figure 29.11***). However, no fracture pattern can exclude significant haemorrhage.

Marvin Tile, b. 1933, orthopaedic surgeon, Sunnybrook Medical Centre, Toronto, Canada.

Type A

Type A are the most common fractures and are completely stable. They result from lateral compression, which causes compression fractures of the pubic rami or compression fracture of the sacrum posteriorly.

Type B

These fractures are partially stable, and there is disruption of the anterior pelvis and partial disruption of the posterior pelvis. The pelvis can open and close 'like a book', but because the sacroiliac ligaments remain intact there is no vertical displacement. Internal or external stabilisation is required. Blood loss can be significant.

Type C

This fracture is completely unstable. Both the anterior pelvis and the entire posterior pelvic complexes are disrupted and the disrupted pelvic bones are free to displace horizontally and vertically. In both type B and type C pelvic injuries, there is a high risk of associated abdominal injuries (bowel perforation or mesenteric laceration) and rupture of the diaphragm.

Clinical examination

Pelvic fractures should be easily identified if ATLS guidelines are followed. There is no role of 'springing' the pelvis. If a binder has not been applied and an 'open book' fracture is suspected, a binder must be immediately applied as the presence of major pelvic fracture is associated with life-threatening blood loss and requires appropriate measures.

Inspection of the skin may reveal lacerations in the groin, perineum or sacral area, indicating an open pelvic fracture, the result of gross deformation. Evidence of perineal injury or haematuria mandates radiological evaluation of the urinary tract from below upwards (retrograde urethrogram followed by cystogram or CT cystogram and an excretory urogram, as appropriate) when the physiology allows. Inspection of the urethral meatus may reveal a drop of blood, indicating urethral damage.

Inspection of the anus may reveal lacerations to the sphincter mechanism. Rectal examination may reveal blood in the rectum and/or discontinuity of the rectal wall, indicating a rectal laceration. In male patients, the prostate is palpated; a high-riding prostate indicates a complete urethral avulsion. A full neurological examination is performed of the perineal area, sphincter mechanism and femoral and sciatic nerves.

Diagnosis

Radiograph

Examination of a plain radiograph of the pelvis requires an understanding of the mechanism of injury and a decision on the stability of the pelvic rim. It is important to note that the vast majority of patients with suspected pelvic fractures may have a pelvic binder in place and hence plain radiograph findings may be normal. FAST may be unreliable as it does not localise intra-abdominal bleeding in these patients. CT is the diagnostic modality of choice in the physiologically non-compromised patient, and CT angiography is particularly helpful in providing details of both the anatomy of the fracture and the origin of the bleeding (venous or arterial).

An open book-type mechanism causes one or both ilia to rotate externally (opening, like a book). A lateral compression mechanism causes the pelvis to collapse. An 'open book fracture' is seen as a widening of the pubic symphysis or widening at the site of a fracture in the pubic ramus. Not only is there disruption of the bony pelvis, but also tearing of the pelvic floor and thus the pelvic venous plexus is at risk. The more unstable the pelvis, the more likely the structures are to be damaged. When the pelvis collapses from a lateral compression injury, the pubic bones usually fracture. Displacement of the anterior pelvis by greater than 2 cm indicates at least partial instability. A vertical shear disruption of the sacroiliac joint with apparent shortening of the limb on the affected side implies significant energy of injury.

Management

The treatment for bleeding is to stop the bleeding!

The priorities for resuscitating patients with pelvic fractures are no different from the standard. These injuries can produce a real threat to the circulation, and management is geared towards controlling this threat. Initial management requires the use of a compression binder or a sheet, applied around the true pelvis at the level of the greater trochanters ('reduce the pelvic volume'), a potentially life-saving procedure that has to be done in the emergency department.

Eighty-five per cent of bleeding originating from the pelvis is of venous origin and can be controlled by non-operative means, including compression either by binding or external fixator or by extraperitoneal pelvic packing (i.e. packing the loose space between the bony wall of the pelvis and the peritoneum) to compress the pelvic veins. If other sources of bleeding have been ruled out, the extraperitoneal pelvic packing is done without entering the peritoneal cavity. This may be combined with external fixation.

If the bleeding is of arterial origin, interventional angioembolisation is the next choice for bleeding control. The techniques for bleeding control (compression, packing, fixation and angioembolisation) do not exclude each other but rather may complement each other. Persistent bleeding after packing may require angioembolisation and vice versa.

Severe pelvic injuries require a multidisciplinary team approach. If adequate orthopaedic experience is unavailable, consideration should be given towards early transfer of this patient to an institution with the necessary expertise.

If the source of the bleeding is in doubt or FAST/CT results are positive, showing a significant amount of blood in the peritoneal cavity, concurrent intra-abdominal injury cannot be excluded and it is wise to perform an exploratory laparotomy to treat or rule out intra-abdominal bleeding.

Summary

In summary, a haemodynamically normal patient can be safely transferred for stabilisation of unstable fractures within hours after injury and following control of the associated damage.

Summary box 29.8

Pelvic injury

- Associated injuries can only be managed once the patient is physiologically non-compromised
- Decision on the stability is of paramount importance
- Procedures for damage control may be the only available option
- External stabilisation of the pelvic ring is the basis of all treatment
- If necessary, further bleeding control can be achieved either by angioembolisation or by extraperitoneal packing

DAMAGE CONTROL

Following major injury, protracted surgery in the physiologically unstable patient can in itself prove fatal. Patients with the 'deadly triad' (hypothermia, acidosis and coagulopathy) are those at highest risk. Damage control or damage limitation surgery is a concept that originated from a naval shipbuilding strategy, whereby ships were designed so that the damage was kept 'local' and only minimal repairs were needed to prevent the ship from sinking while definitive repairs waited until it had reached port. The technique has been adopted following major trauma and includes initial care and resuscitation (damage control resuscitation) and the surgical correction of the injury (damage control surgery).

The minimum amount of surgery needed to stabilise the patient's condition may be the safest course until the physiological derangement can be corrected. Damage control surgery is restricted to only three goals:

- stopping any active surgical bleeding;
- controlling any contamination;
- restoring normal physiology.

Once the first two have been achieved then the operation is suspended and the abdomen temporarily closed to allow for restoration of physiology to occur. The patient's resuscitation then continues in the ICU, where other therapeutic interventions can take place. Once the physiology has been corrected, the patient warmed and the coagulopathy corrected, the patient is returned to the operating theatre for any definitive surgery.

Damage control resuscitation

The concept of damage control has been broadened to include the techniques used in resuscitation as well as in surgery. The time in the emergency department is minimised and the majority of resuscitation of the patient is carried out in the operating theatre and not in the resuscitation bay (*Table 29.6*). Resuscitation is individualised through repeated point-of-care testing of haemoglobin, acidosis (pH and lactate) and clotting, and is therefore directed towards the early delivery of biologically active colloids, clotting products and whole blood in order to buy time. The physiological disturbances that are associated with the downward spiral of acidosis, coagulopathy and hypothermia in these serious injuries are predicted and attempts are made to avoid them rather than react to them.

Damage control surgery

This is a key component of damage control resuscitation. The decision of whether damage control surgery is the appropriate course should be made early (*Table 29.7*) and allows the whole surgical and anaesthetic team to work together to limit the time in surgery and achieve the earliest possible admission of the patient to the ICU. Damage control is a staged process.

The initial focus is haemorrhage control, followed by control and limitation of contamination, which are achieved using a range of abbreviated techniques including simple ligation of bleeding vessels, shunting of major arteries and veins, drainage, temporary stapling of bowel and therapeutic packing.

Following the above, the abdomen is closed in a temporary fashion either by using commercially available products or by using a sheet of plastic (e.g. OPSITE◊ or similar product) over the bowel, an intermediate pack to allow suction and a further sheet of adherent plastic drape to the skin to form a watertight and airtight seal. Suction is applied to the intermediate pack area to collect abdominal fluid. This technique is known as the 'Vac-Pac' or 'OPSITE◊ sandwich' (*Figure 29.12*). As soon as control has been achieved the patient is transferred to the ICU, where resuscitation is continued.

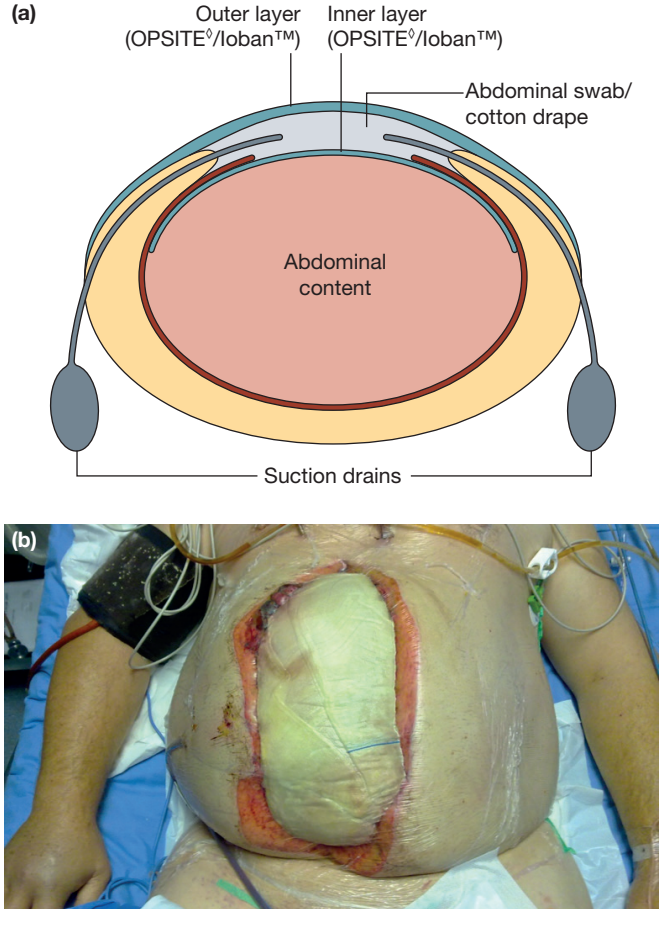

Figure 29.12 (a) Diagram showing temporary skin closure in damage control. **(b)** Abdominal closure following damage control surgery showing an OPSITE◊ closure.

TABLE 29.6 The stages of damage control surgery.

Stage	Intervention
I	Patient selection
II	Control of haemorrhage and control of contamination
III	Resuscitation continued in the intensive care unit
IV	Definitive surgery
V	Abdominal closure

The next stage following damage control surgery and physiological stabilisation is definitive surgery. The team should aim to perform definitive anastomoses, vascular reconstruction and closure of the body cavity within 24–72 hours of injury. However, this must be individualised to the patient, the response to critical care resuscitation and the progression of injury.

TABLE 29.7 Indications for damage control surgery.

Anatomical	• Inability to achieve haemostasis • Complex abdominal injury, e.g. liver and pancreas • Combined vascular, solid and hollow organ injury, e.g. aortic or caval injury • Inaccessible major venous injury, e.g. retrohepatic vena cava • Demand for non-operative control of other injuries, e.g. fractured pelvis • Anticipated need for a time-consuming procedure
Physiological (decline of physiological reserve)	• Temperature <34°C • pH <7.2 • Serum lactate >5 mmol/L (normal: <2.5 mmol/L) • Prothrombin time >16 s • Partial thromboplastin time >60 s • >10 units blood transfused • Systolic blood pressure <90 mmHg for >60 min
Environmental	• Operating time >60 min (core temperature loss is usually 2°C/h) • Inability to approximate the abdominal incision • Desire to reassess the intra-abdominal contents (directed relook)

The abdomen is closed as soon as possible, bearing in mind the risks of abdominal compartment syndrome (ACS). The closure is not without its own morbidity. Successful closure may require aggressive off-loading of fluid and even haemofiltration to achieve this if the patient will tolerate it. The best situation is closure of the abdominal fascia, or, if this cannot be achieved, then skin closure only. Occasionally, mesh closure can be used, with skin grafting over the mesh and subsequent abdominal wall reconstruction.

Thoracic damage control is conceptually based on the same philosophy. This is that haemorrhage control and focused surgical procedures minimise further surgical insult and lead to improved survival in the unstable trauma patient. The aim is to control bleeding and limit air leaks using the fastest procedures available, such as staplers, to minimise the operative time.

The indications and techniques for emergency thoracic surgery have already been described.

Damage control applies equally to the extremities. In this case, it is shunting of blood vessels, identifying and marking damaged structures such as nerves, fasciotomy and removal of contaminated tissue that are the main tasks. Subsequent definitive management can be carried out at a later stage.

Summary box 29.9

Damage control

- Resuscitation is carried out in the operating theatre using biologically active fluids (i.e. blood) – damage control resuscitation
- The surgery performed is the minimum needed to stabilise the patient
- The aims of surgery are to control haemorrhage and limit contamination
- Secondary surgery is aimed at definitive repair

ABDOMINAL COMPARTMENT SYNDROME AND THE OPEN ABDOMEN

Raised intra-abdominal pressure has far-reaching consequences for the patient; the syndrome that results is known as ACS. ACS is a major cause of morbidity and mortality in the critically ill patient and its early recognition is essential (*Table 29.8*).

In all cases of abdominal trauma in which the development of ACS in the immediate postoperative phase is considered a risk, the abdomen should be left open and managed as for damage control surgery.

TABLE 29.8 Effect of raised intra-abdominal pressure on individual organ function.

System	Effect
Renal	Increase in renal vascular resistance leading to a reduction in glomerular filtration rate and impaired renal function
Cardiovascular	Decrease in venous return resulting in decreased cardiac output because of both a reduction in preload and an increase in afterload
Respiratory	Increased ventilation pressures because of splinting of the diaphragm, decreased lung compliance and increased airway pressures
Visceral effects	Reduction in visceral perfusion
Intracranial effects	Severe rises in intracranial pressures

INTERVENTIONAL RADIOLOGY

Interventional radiology can be useful in the management of torso trauma as both an investigative and a therapeutic tool for patients with vascular injury. Angioembolisation following demonstration of ongoing bleeding in splenic and renal injury is a valuable technique.

NON-OPERATIVE MANAGEMENT

Non-operative management is generally preferred for the management of solid organ injury in physiologically non-compromised children. Non-operative management of solid abdominal organ injury has rapidly gained acceptance in the management of adults as well. A stable patient and accurate CT imaging are prerequisites for this approach. Failure of non-operative management is uncommon and typically occurs within the first 12 hours after injury. Therefore, if correctly selected, the vast majority of these patients will avoid surgery, require less blood transfusion and sustain fewer complications than operated patients.

ANTIBIOTICS IN TORSO TRAUMA

There is no level 1 evidence to recommend the use of antibiotics for the insertion of chest drains. However, prophylactic antibiotics prior to surgery should be used in all cases of penetrating abdominal trauma. Unless there is major contamination, a single dose is sufficient.

FURTHER READING

American Association for the Surgery of Trauma. *Organ injury scaling system*. Available from http://www.aast.org (accessed February 2022).

American College of Surgeons. *Advanced trauma life support course manual for doctors*, 10th edn. Chicago, IL: American College of Surgeons, 2020.

Boffard KD (ed.). *Definitive surgery of trauma care*, 5th edn. London: Taylor and Francis, 2019.

Eastern Association for the Surgery of Trauma. *Guidelines for practice management: evidence-based guidelines*. Available from http://www.east.org (accessed February 2022).

Feliciano DV, Mattox LK, Moore EE (eds). *Trauma*, 9th edn. New York, NY: McGraw Hill, 2020.

Khan MA, McMonagle M (eds). *Trauma: code red: companion to the RCSEng definitive surgical trauma skills course*. Boca Raton, FL: CRC Press, 2018.

Khan MA, Nott D (eds). *Fundamentals of frontline surgery*. Boca Raton, FL: CRC Press, 2021.

Tornetta P, Ricci W, Court-Brown CM *et al*. *Rockwood and Green's fractures in adults*, 9th edn. Philadelphia, PA: Wolters Kluwer, 2019.

World Society for Abdominal Compartment Syndrome. *Abdominal compartment syndrome*. Available from http://www.wsacs.org (accessed February 2022).